

**Department of Defence**

Australian Army Malaria Institute

→ TO (John Donohoe)  
ENG (Barry Thompson)  
Ned the  
20/11/01

To:	Dr. Barry Thompson Department of Adverse Drug Reactions Therapeutics Goods Administration
Fax:	02 6232 8392
Tel:	
Email:	

From:	<b>LT M.G REID</b> Australian Army Malaria Institute Weary Dunlop Drive Gallipoli Barracks Enoggera Queensland AUSTRALIA 4051
Fax:	+ 61 7 3332 4800
Tel:	+ 61 7 3332 4816
Email:	mark.reid1@defence.gov.au

**Subject: TAFENOQUINE SAFETY ALERT****Reference: 548-7-41****Date: 03 July 2001****Pages (including cover): 66**

**IMPORTANT:** This facsimile remains the property of the Defence Organisation and is subject to the jurisdiction of section 70 of the Crimes Act 1914. If you have received the facsimile in error, you are requested to immediately contact the sender by telephone so that arrangements can be made for the return of the document to the sender.

**Instructions or comments:**

Dear Sir,

In accordance with statutory and ethics committee requirements please find enclosed a safety alert provided by Glaxo SmithKline relating to the anti-malarial drug tafenoquine succinate.

This safety alert relates to two trials conducted by the Australian Army Malaria Institute:

Protocol number SB 252263/033 (ADMEC 216/00, TGA CTN 2000/239)

Protocol number SB 252263/046 (AMI TQ004)

Further information will be sent as it becomes available. Please confirm receipt of this document by email or fax by COB on the day of receipt.

Mark Reid  
Lieutenant

3 July 01

03 JUL 2001

Department of Defence

**MINUTE**

548-7-41

**Dr. Barry Thompson** Department of Adverse Drug Reactions, TGA F: 02 6232 8392

**FURTHER SAFETY WARNING FOR TAFENOQUINE**

1. A further safety warning regarding tafenoquine is being forwarded by e-mail as this document is large. This further warning covers findings of renal neoplasia in male Sprague-Dawley rats. This is considered by the GSK toxicologists to be unrelated to the potential effects in humans, to be species specific and perhaps even specific for the genetic lineage in which it was demonstrated. You will also note from the reports that this was found from a large dose of tafenoquine over the life of the rat.

2. Adherence to the scheduled review of those volunteers being routinely followed with ophthalmic review is recommended. The next review will occur within two weeks with results available approximately at the end of this month. The USAMMDA is also sending an ophthalmologist (MAJ J Brown) to assist the trial ophthalmologist with this assessment.

3. A copy of the report has been forwarded to TGA also.

4. Forwarded for your information.



S J KITCHENER  
MAJ  
OC CLINICAL FIELD

ARMY MALARIA INSTITUTE  
Tel: 07 3332 4836; Fax: 07 3332 4800  
Email: scott.kitchener@defence.com.au

03 Jul 01

03 JUL 2001

**CONFIDENTIAL****Letter to the Regulatory Authorities****TO WHOM IT MAY CONCERN**

3rd July 2001

Dear Sirs

**Preliminary Results of a Two Year Carcinogenicity Study of  
SB-252263-AX (Tafenoquine) in Sprague-Dawley Rats****Abstract**

Tafenoquine treatment (2.0 mg/kg/day orally for 2 years) appears to be associated with an increased incidence of renal cell tumours and hyperplasia in male rats. Kidneys of males from other dose groups (1.0, 0.5 and 0.1 mg/kg/day) are being evaluated. Drug-induced increases in kidney tumors were not observed in female rats given 2.0 mg/kg/day. The equivalent mouse study is not expected to report till mid-2003 so comparative data in that species are not available. The mechanism appears to be non-genotoxic and related to daily dosing for periods approaching the lifetime of the rats. In the context of clinical trial use the weight of current evidence indicates that the findings in the rat carcinogenicity study do not predict any hazard to human in the studies conducted to date.

**Introduction**

Tafenoquine (SB-252263-AX, the succinate salt of SB-252263; also referred to as WR238605 succinate), is an 8-aminoquinoline derivative, and is an antimalarial compound. Clinical trials for its potential use in malaria prophylaxis have been conducted with doses of up to 600 mg once a week for up to 10 weeks, and up to 200 mg administered once a week for up to 6 months, but there are currently no trials with patients or volunteers actually receiving drug.

**Study Design**

The rat carcinogenicity study has been conducted at SRI (Southern Research Institute), Birmingham, Alabama. In a previous 3-month study [2] (doses 0.5, 6 and 18 mg/kg/day) and 6-month study [3] (doses 0.5, 2 and 9 mg/kg/day) drug-

03 JUL 2001

related changes, particularly in lung, were considered too severe at 6 or 9 mg/kg/day for use in the two year study, so a dose of 2 mg/kg/day was selected as the high dose for this study. Tafenoquine was therefore given daily, by oral gavage, to male and female Sprague-Dawley rats (CD® strain, Charles River Breeding Laboratories, Inc; 50/sex/group) at dosages of 0.1, 0.5, 1.0 and 2.0 mg/kg/day (in terms of SB-252263). Two additional groups (50/sex) received an equivalent volume of the vehicle (1.0% methylcellulose and 0.2% Tween 80 in deionized water). Rats were 5 to 6 weeks of age at the start of dosing and were dosed daily for approximately 24 months or until survival in the sex/group fell to approximately 15 individuals. All rats killed for humane reasons or dying during the study were subject to full *post mortem* examination, as were all surviving rats at the end of the study.

#### **Preliminary results:**

**Survival at the end of study:** Survival in male control groups was not as good as in treated groups. Male survivors in one control group (V1) were killed on Day 703, and the male survivors in the second control group (V2) were killed on Day 631. The decision to terminate these groups was taken when survival fell to approximately 15 individuals. Surviving high dose males (2.0 mg/kg/day) were killed at the scheduled study termination, on Day 731.

**Microscopic observations:** On microscopic examination of tissues it became evident that more male rats given 2.0 mg/kg/day of tafenoquine had renal tumors and hyperplastic lesions in kidney than control rats. It is important to note that the primary slide reading by the study pathologist is still ongoing, so findings have not yet been subject to formal Peer Review or audit by the Quality Assurance unit. However, key slides of kidney have now been reviewed and diagnoses agreed by a pathologist from GSK. Final numbers may change slightly, but the increase in tumours is not in doubt.

Current data indicate that 9 animals at 2.0 mg/kg/day had renal cell tumours compared to none in either control group (see Table 1). In addition 6 males at 2.0 mg/kg/day had renal cortical hyperplasia, compared to none in either control group. Kidneys from animals in the groups dosed with tafenoquine at lower dosages have not yet been examined, so at this point in time it is not possible to comment on dose-response relationship.

There was no effect on incidence of tumours in female rats at 2.0 mg/kg/day compared with controls.

03 JUL 2001

Males with renal tumours were all either killed at termination (5 animals, on Day 731) or died in the last 6 weeks of the study (2 on Day 689, 1 on Day 698, 1 on Day 726).

The renal tumours in male rats were seen against a background of chronic progressive nephropathy, a common condition in aging male rats. There was a tendency towards increased incidence and severity of the background nephropathy in the high-dose rats compared with controls (see Table 1).

**Table 1: Incidence of Selected Renal Lesions in Male Rats**

Dose Group (Dosage)	V1 (Control)	V2 (Control)	D (2.0 mg/kg)
Day of Terminal Kill	703	631	731
Number Examined (kidney)	49	50	48
<b>Incidence:</b>			
Chronic progressive nephropathy			
trace	8	15	2
mild	16	10	19
moderate	12	5	14
severe	5	2	11
(total)	(41)	(32)	(46)
Hyperplasia, cortical	0	0	6
Renal cell adenoma (benign)	0	0	8
Renal cell carcinoma (malignant)	0	0	1
(total renal cell tumours)	(0)	(0)	(9)

### Discussion

The unequal terminal kill dates for control groups compared with treated groups is a complicating factor in interpreting these data. It can be seen that the surviving high-dose animals were killed approximately 3 months after one control group, and one month after the other. It is possible that the additional survival time allowed development of renal tumours in the affected animals by chance. However, the final number of animals with tumours (9/48) is higher than would be

expected for this strain of rat at this age, and the presence of hyperplastic lesions in some other rats in the same treatment group, again with none seen in controls, suggests an underlying relationship to drug treatment.

Tafenoquine has been shown to cause damage to kidneys in rats in previous studies. In an 8-week study, acidophilic droplets were seen in renal tubular cells with an increased severity and incidence in both male and female rats treated at 9.0 mg/kg/day, accompanied by brown pigment deposits [1]. In a 13-week study, "proteinic cytoplasmic droplets" were accompanied by degenerative changes in tubular epithelium (vacuolation, necrosis), as well as brown pigment deposits, at doses of 6 and 18 mg/kg/day in male and female rats [2]. The changes in that study were termed "haemoglobin nephrosis" and deemed to be secondary to haemolytic anaemia. In a 6-month study, pigment was noticed in kidney tubules at 2 and 9 mg/kg/day, but acidophilic or "proteinic" droplets were not described [3].

It is known that tafenoquine can cause methaemoglobinaemia, and resultant increased red-cell turnover. Changes described in kidney in the studies discussed above might be due wholly or in part to haemoglobin leakage through glomeruli and subsequent re-uptake by tubular epithelial cells. This mechanism was suggested in the report of the 3-month study [2] and similar changes have been described in the literature [4]. It is also possible that the acidophilic ("proteinic") droplets, at least in male rats, were partly due to accumulation of alpha-2 microglobulin ( $\alpha$ -2- $\mu$ -globulin). Although there is at present no direct evidence of this, the microscopic appearance of acidophilic droplets in renal tubules was similar to the appearance of  $\alpha$ -2- $\mu$ -globulin accumulation in male rats (so-called "hydrocarbon nephropathy" [5, 6, 7]). This is known to be specific to male rats, so cannot fully explain findings noted in both sexes in earlier studies, but is known to be a potential promotor of renal tumorigenesis in male rats [5, 6, 7].

Tafenoquine is also known to cause changes consistent with phospholipid accumulation in various tissues, particularly lung [1]. Although kidney has not been shown to be a target for phospholipid accumulation with tafenoquine treatment in rats, kidney tubular epithelium is a known potential target for this change, and it is possible that minor changes to phospholipid metabolism are occurring in kidney tubules which might be contributing to the nephropathy seen in animal studies.

Clearly, whatever the mechanism, there is evidence of kidney damage in rats with prolonged administration of tafenoquine, and this is borne out in the rat carcinogenicity study by the apparent increased incidence and severity of chronic progressive nephropathy. It can be hypothesised that chronic damage/repair

03 JUL 2001

cycling in the kidney could have promoted renal cell hyperplasia and neoplasia in this study. It is proposed that the increase in hyperplastic and neoplastic changes in the male rats in this study is likely to have been secondary to the degenerative kidney changes caused by the drug.

The fact that all the tumours were observed in animals killed or dying in the last months of the study is consistent with a non-genotoxic (indirect) mechanism for tumour promotion by drug treatment. In addition, the presence of a promotion effect only in males is circumstantial evidence of involvement of accumulation of  $\alpha$ -2- $\mu$ -globulin as part of the drug effect; this is known to be specific to male rats and is known to be a potential promotor of renal tumorigenesis [5, 6, 7]. Moreover, because effects mediated via  $\alpha$ -2- $\mu$ -globulin are male rat specific, tumours promoted by this mechanism are considered to be of little relevance to human risk assessment.

Tafenoquine has been tested in a series of genotoxicity assays the results of which indicate that Tafenoquine does not pose a genotoxic risk to man. This, plus the findings discussed above, support the contention that the renal tumorigenesis in rats is a non-genotoxic phenomenon, secondary to chronic renal pathology associated with prolonged repeat daily dosing. It is generally recognised that non-genotoxic tumorigenic agents represent a much lower risk to human than those with a genotoxic mechanism. It is also important to note that there has been no evidence of renal toxicity in human recipients of tafenoquine in any of the trials to date. Given that the mechanism appears to be non-genotoxic and related to daily dosing for periods approaching the lifetime of the rats, in the context of clinical trial use the weight of current evidence indicates that the findings in the rat carcinogenicity study do not predict any hazard to human in the studies conducted to date.

### Conclusion

Tafenoquine was associated with an increased incidence of renal cell hyperplasia and neoplasia at 2.0 mg/kg/day in male rats in a two-year study. The weight of evidence at hand suggests this increase in tumours does not predict a hazard to man.

### References

- 1 SB Report No: SB-252263/RSD-1013ST/1 (December 1999)  
Histopathology of tissues from study SBF/232 "SB-252263-AX: an 8-week oral gavage study in rats to investigate the pharmacokinetics of SB-252263

03 JUL 2001

and the effect on hepatic levels of cytochrome P450 and related parameters"

2. University of Illinois at Chicago/Toxicology Research Laboratory Study No 098 (1993)  
Thirteen week oral toxicity study of WR238605 succinate in rats.
3. SB Report No. SB-252263/RSD-1018S9/1 University of Illinois at Chicago/Toxicology Research Laboratory Study No 152 (March 1997)  
Six month oral toxicity study of WR238605 succinate in rats.
4. Cheville, NF. 1983. Cell Pathology (2nd edition) page 578 (Iowa State University Press, Ames, Iowa, USA)
5. Alden, C.L. (1986) A review of unique male rat hydrocarbon nephropathy. Toxicol. Pathol. 14, 109-111.
6. Borghoff, S.J., Short, B.G. and Swenberg, J.A. (1990) Biochemical mechanisms and pathobiology of alpha 2 microglobulin nephropathy. Annu. Rev. Pharmacol. Toxicol., 30, 349-367.
7. Borghoff, S.J. and Lagarde, W.H. (1993) Assessment of binding of 2,4,4-trimethyl-2-pentanol to low molecular weight proteins isolated from kidneys of male rats and humans  
Toxicology and Applied Pharmacology, 119, 228-235.

03 JUL 2001



**CONFIDENTIAL****Letter to the Regulatory Authorities****TO WHOM IT MAY CONCERN****3rd July 2001**

Dear Sirs

**Summary**

The purpose of this follow up **Safety Report** dated 3rd July 2001 is to update Regulatory Agencies, Ethics Committees and Investigators of safety findings related to the monitoring for the effects of phospholipidosis in a Phase III Tafenoquine clinical study.

A preliminary report focused on an initial group of 33 subjects was submitted to those Regulatory Agencies, Ethics Committees and Investigators involved in ongoing clinical trials on 9-May 2001 and is attached in full as Appendix A.

These data are from a group of subjects ( $n = 95$ ) in a Phase III study (Study 252263/033) investigating the safety, tolerability and effectiveness of tafenoquine in the prophylaxis of malaria in non-immune Australian soldiers deployed to East Timor.

This Safety Report is in three parts

**Part A**

Details on two subjects (subject numbers 51 and 59 in Appendix F) dosed with tafenoquine for 6 months, that had retinal abnormalities on visual examination (ophthalmoscopy) of the fundus, and have abnormal findings reported on fluorescein angiogram examination of the retina.

**Part B**

Ophthalmological (corneal examination, visual acuity, visual field, colour vision, retinal examination, fluorescein angiogram) data are presented on the 95 subjects within this group, 74 of whom were receiving tafenoquine and 21 of whom were receiving mefloquine.

**Part C**

Lung function testing (diffusing capacity of carbon monoxide --  $D_LCO$ ) data are presented on the 95 subjects within this group, 74 of whom were receiving tafenoquine and 21 of whom were receiving mefloquine.

03 JUL 2001

Details of examinations are given in the Safety Report but in summary the following findings are reported across 95 subjects after 6 months weekly dosing:

- 1) corneal changes (a vortex keratopathy) have been seen in 65 of 74 tafenoquine subjects, but in none of the 21 mefloquine subjects
- 2) minor visual acuity and colour vision changes are reported across both treatment groups
- 3) on a screening Amsler grid assessment possible mild visual field changes were reported in 8 tafenoquine subjects, and in 2 mefloquine subjects. However, on formal Amsler grid assessment only one was abnormal (a tafenoquine subject)
- 4) retinal examination demonstrate granularity/pigmentation of the retinal pigment epithelium (RPE) in 22 tafenoquine subjects and 2 mefloquine subjects; hard drusen were seen in 6 tafenoquine subjects and 1 mefloquine subject.

All examinations were reported as normal at baseline (before study medication).

- 5) A group of 10 subjects with retinal changes (9 tafenoquine subjects and 1 mefloquine subject) proceeded to fluorescein angiogram examination. Seven examinations were reported as normal, three had abnormalities (2 tafenoquine subjects and 1 mefloquine subject). No fluorescein angiograms were carried out at baseline.

Similar corneal changes (vortex keratopathy) have been observed with other cationic amphiphilic agents. However given the requirement to establish the reversibility of these changes off study drug, and more fully investigate the associated ophthalmological changes, GlaxoSmithKline have voluntarily suspended all tafenoquine dosing across both the adult and paediatric programmes. The current status of the IND is inactive.

## BACKGROUND

### Phospholipidosis monitoring data from Phase III: Study 252263/033

Study 033 is a randomised, double-blind, comparative study to evaluate the safety, tolerability and effectiveness of tafenoquine and mefloquine for the prophylaxis of malaria in non-immune Australian soldiers deployed to East Timor.

A total of 652 subjects were randomised in October 2000 in a 3:1 ratio to either tafenoquine (approximately 490 subjects) or mefloquine (approximately 160 subjects) and then deployed into East Timor for 6 months peace-keeping duties. Having completed this period of deployment and study medication the soldiers are now coming out of area and returning to Australia.

Phospholipidosis has been observed in animal toxicology studies. Phospholipidosis is common to this type of compound (cationic amphiphilic) and is characterised by the excessive accumulation of intracellular phospholipids. Effects seen in animal studies were principally manifested in the lung with accumulation of foamy macrophages and back-up of surfactant, although any tissue in the body may be affected. Following expert consultation a monitoring programme was devised to further assess the potential of tafenoquine to induce phospholipidosis in humans. This focussed on a subset of approximately 100 subjects in Study 252263/033. Non-invasive techniques were chosen for monitoring three targets in Study 252263/033: lung, eye and peripheral lymphocytes.

This subset had assessments performed at baseline, before deployment, and at 6 months as they were leaving the endemic area and having completed study medication. The assessments chosen are as outlined in Appendix A – i.e. eye examinations, lung function testing, and collection of blood samples for EM examination of peripheral lymphocytes. In view of the nature and location of this study it was not possible logistically to select either a larger group of subjects, or perform more frequent examinations.

Data on the full group of 95 subjects were unblinded on 21-May-2001 via the Independent Data Monitoring Committee that oversees the adult programme to assist in data interpretation and subsequent follow-up activities. The data are summarised below and presented in full in the Appendix F. In order to maintain the blind, data are not presented with individual patient identifiers.

## PART A

Of those subjects (n=38) with findings on visual examination (ophthalmoscopy) of the retina (see below in Part B) ten were selected for fluorescein angiogram examination. This group represented those subjects considered by the two ophthalmologists (Dr Gary Lillicrap, M.B., B.S., D.O., F.R.A.C.O., F.A.C.T.M, Townsville, Australia, and Major Jeremiah Brown, M.S., M.D., Director, Ophthalmology Research, US Army Medical Research Detachment) most appropriate for additional examination

Fundus fluorescein angiography is employed to assess the physiology of the retinal and choroidal circulation, and for demonstrating disease processes of the macula. Photographs of the retina are taken after intravenous injection of fluorescein dye.

Injected fluorescein is 80% bound to albumin and 20% free. Retinal capillaries and major choroidal vessels are impermeable to both free and bound fluorescein. The choriocapillaris vessel walls are thin and leaky and free fluorescein will leak out, but cannot penetrate an intact retinal pigment epithelium (RPE) because of the tight junctions between RPE cells.

In a normal angiogram only the retinal circulation will be visible, with a background choroidal fluorescence. Hyperfluorescence is indicative of several syndromes. In an 'RPE window defect' fluorescein escapes through the tight junctions, represents focal atrophy of this cell layer, is associated with multiple pathology, and the fluorescein escape should fade as the angiogram progresses. 'Leakage' is indicative of more active pathology, such as abnormal blood vessels or the RPE cells not functioning, and dye continues to accumulate as the angiogram progresses.

Two of the 9 tafenoquine subjects had abnormal findings reported:

**Left eye:** There are several perifoveal pinpoint areas of hyperfluorescence, which appear early in the angiogram and persist through the late frames. Several of these spots demonstrate mild fluorescein leakage.

**Right eye:** Normal.

Of the other ophthalmological assessments corneal deposits were observed at 6 months, visual acuity was improved from baseline to 6 months (6/5, 6/5 to 6/4, 6/4), colour vision was unaltered from baseline to 6 months, and both screening and formal Amsler assessments were normal at both baseline and 6 months. On visual examination (ophthalmoscopy) of the retina granulation of the RPE was reported in the left eye only.

[REDACTED]  
**Left eye:** There is a single pinpoint area of hyperfluorescence (RPE window defect) at the edge of the foveal avascular zone. There is no leakage of dye. This area appears to correspond to a drusen noted on colour photography (see Part B for definition).

**Right eye:** Normal

Of the other ophthalmological assessments corneal deposits were observed at 6 months, visual acuity was unaltered from baseline to 6 months, colour vision was reduced by a single Ishihara plate from baseline to 6 months, and both screening and formal Amsler assessments were normal at both baseline and 6 months. On visual examination (ophthalmoscopy) of the retina minimal to moderate pigmentation of the macula was reported, but within normal limits.

Of note the single mefloquine subject that proceeded to angiogram had abnormalities as follows:

[REDACTED]  
**Right eye:** The angiogram demonstrates three pinpoint areas of hyperfluorescence which fade late in the study (RPE window defect). There is no leakage of fluorescein.

**Left eye:** Normal

Of the other ophthalmological assessments corneal deposits were absent at 6 months, visual acuity was unaltered from baseline to 6 months, colour vision was unaltered from baseline to 6 months, and both screening and formal Amsler assessments were normal at both baseline and 6 months. On visual examination (ophthalmoscopy) of the retina granularity/pigmentation of the macula was reported.

Each of the angiograms demonstrates focal pinpoint areas of abnormal hyperfluorescence in the perifoveal region. These abnormalities appear to be at the level of the RPE. Each study demonstrates an abnormality in only one eye. These findings are nonspecific. When performing angiography in a population of young asymptomatic people, such abnormalities as these may, on occasion, be reported. In one published paper 20 of 48 normal people demonstrated some sort of minute abnormality on fluorescein angiography.<sup>1</sup> Common causes of focal abnormalities at the level of the RPE in young people include central serous retinopathy, solar retinopathy, past inflammatory disease, etc. Interpretation in this case is limited by the fact that there are no baseline studies for comparison. Although these findings are subtle and unilateral an early drug effect can not be excluded. Subject 59 has the most subtle finding while the angiogram on subject 51 is clearly abnormal.

1. Nielsen NV. The normal fundus fluorescein angiogram. II. A longitudinal fluorescein angiographic study of the fundus in clinically healthy subjects without ophthalmoscopically abnormalities. Acta Ophthalmol (Copenh) 1985 Jun;63(3):305-10.

## Summary

Of 95 subjects dosed with either tafenoquine or mefloquine for 6 months, 38 had findings on dilated funduscopy of which 10 subjects (9 tafenoquine and 1 mefloquine) were selected to have fluorescein angiogram examination on completion of study medication on the basis of findings on dilated funduscopy – i.e. granularity/pigmentation of the RPE.

No fluorescein angiograms were performed on any subject before commencing study drug.

Of the 10 angiograms 3 are reported as abnormal. Of these, 2 (one tafenoquine and one mefloquine) have pinpoint areas of hyperfluorescence only; the third also demonstrates leakage of fluorescein, and is clearly abnormal (a tafenoquine subject).

Eight additional subjects, not available at the first follow-up visit, are to have fluorescein angiogram examinations within the next few weeks. Repeat angiograms will also be performed on the three subjects discussed above.

In the absence of baseline data it is not yet possible to determine the relevance of these structural changes to either retinal function or administration of study drug. External advice is being sought as to how to better characterise, and determine the clinical significance, of these findings.

## PART B

### EYE EXAMINATIONS

#### 1. Corneal changes

On slit lamp examination corneal deposits with a vortex pattern were observed in 65 of 74 (88%) tafenoquine subjects. All subjects were asymptomatic. No corneal changes were seen with any of the 21 mefloquine subjects.

The appearance of these changes is that of yellowish brown corneal epithelial deposits, symmetrical and bilateral in a vortex pattern below the pupil with a swirl outward and in all cases sparing the limbus. In two subjects (subject 73 and subject 74 in Appendix F) who had had a Lasik correction surgery of myopia to one or both eyes this epithelial whorl was centrally placed over the optical axis in the eye(s) that has had the previous Lasik whilst, in the unoperated eye it was in the normal position, i.e. below the optical axis.

This finding is identical to the appearance seen following the administration of several other drugs such as amiodarone and chloroquine.

Keratopathy at 6 mths	Tafenoquine (%)	Mefloquine (%)
Yes	65* (88%)	0 (0%)
Possible	4 (5%)	0 (0%)
No	5 (7%)	21 (100%)
ALL	74 (100%)	21 (100%)

\* 6 subjects are reported as very prominent changes, the majority mild changes.

#### 2. Visual acuity

Visual acuity was assessed at baseline and then at 6 months using Snellen charts. A 'screening' visual acuity was performed by the Australian Army physicians/technicians in the army barracks, and was repeated at the ophthalmologists office. Whilst the barracks recording went only as low as 6/6 ('normal acuity'), the ophthalmologist recorded down to both 6/5 and 6/4 (better than normal). It is the ophthalmologists recording that is tabulated in Appendix F.

Across the two treatment groups a similar percentage of subjects had slight improvements, reductions, and unaltered visual acuity at 6 months compared to baseline.



Visual acuity at 6 mths	Tafenoquine (%)	Mefloquine (%)
Reduced	17 (23%)	5 (24%)
Unaltered	29 (39%)	6 (28%)
Improved	28 (38%)	9 (43%)
Unknown	0 (0%)	1 (5%)
ALL	74 (100%)	21 (100%)

Of the 17 tafenoquine subjects that had a reduction in visual acuity over the 6 month period, in 12 the reduction was by one line of the Snellen chart in both eyes.

In a further 2 subjects the reduction was by 2 lines in both eyes, but in every case was a change from 6/4, 6/4 to 6/6, 6/6 and not considered clinically significant.

In subject 73 and subject 74 (Appendix F) the reduction was by 3 lines in one eye, and by 1 or 2 lines in the other eye. Both reductions (6/6, 6/6 to 6/9, 6/12 and 6/5, 6/5 to 6/9, 6/6 respectively) are considered clinically significant changes. Both subjects have had previous Lasik correction surgery of myopia, which may be associated with such a drift in visual acuity over time. Subject 73 was one of the original 5 tafenoquine subjects with changes considered to be clinically significant at the time of the initial IND Safety Report.

Visual acuity reduction	Tafenoquine subjects	Mefloquine subjects
1 line / 1 line	12	1
1 line / 2 lines	1	3
1 line / 3 lines	1*	0
2 lines / 2 lines	2**	1**
2 lines / 3 lines	1*	0
Total	17	5

\* Previous bilateral Lasik surgery & scars.

\*\* Drop to 6/6, 6/6

### 3. Colour vision

Colour vision was assessed using Ishihara colour plates. The number of correctly reported plates was compared from baseline to 6 months, e.g. -1 is equivalent to the subject scoring one more plate incorrect at 6 months compared to their overall score at baseline.

Across the two treatment groups a similar percentage of subjects had slight improvements, reductions, and unaltered colour vision at 6 months compared to baseline when using this technique for assessment.

Of the 18 tafenoquine subjects with a reduction in colour vision only 6 had corresponding reductions in visual acuity as outlined above. The single subject (subject 2 in Appendix F) with a reduction of -3 in colour vision had unaltered visual acuity at 6 months.

Colour vision at 6 mths	Tafenoquine (%)	Mefloquine (%)
Reduced:	18 (24%)	5 (24%)
-1	12	3
- 2*	5	2
-3	1	0
Unaltered	54 (73%)	14 (66%)
Improved	2 (3%)	1 (5%)
Unknown	0 (0%)	1 (5%)
ALL	74 (100%)	21 (100%)

\* includes 1 known red/green colour deficiency on tafenoquine

#### 4. Amsler grid testing – visual fields

Visual fields were assessed by a 'screening' Amsler grid examination performed by the Australian Army physicians/technicians in the army barracks, and then followed by a 'formal' Amsler assessment at the ophthalmologists office.

As discussed in the initial IND Safety Report the first group of 33 subjects that were assessed had normal screening Amsler examinations. However, mydriatics were then applied in preparation for retinal examination, but prior to formal Amsler assessment. In retrospect this sequence of events should not have taken place. Of the 26 tafenoquine subjects examined in this manner 4 were reported to have mild visual field changes on formal Amsler testing. Dilatation of pupils may have affected the results. No such changes were reported in the mefloquine subjects. Together with subject 73 discussed above in section 2, these 4 tafenoquine subjects (subjects 26, 32, 46, 95 in Appendix F) completed the original group of 5 with changes considered to be clinically significant at the time of the initial IND Safety Report. However, formal Amsler assessments without mydriatics have subsequently been repeated on these 4 tafenoquine subjects and are reported as normal.

The remaining 62 subjects in this cohort of 95 were examined both screening and formal Amsler assessments were performed on undilated pupils.

	Amsler grid			
	Screening assessment at 6 mths		Formal assessment at 6 mths	
	Tafenoquine (%)	Mefloquine (%)	Tafenoquine (%)	Mefloquine (%)
Abnormal	8 (11%)	2 (10%)	1* (1%)	0 (0%)
Normal	63 (85%)	19 (90%)	73 (99%)	21 (100%)
Unknown	3 (4%)	0 (0%)	0 (0%)	0 (0%)
ALL	74 (100%)	21 (100%)	74 (100%)	21 (100%)

\* Subject reported discolouration behind the grid, considered by the ophthalmologist to be of doubtful significance.

This table excludes the 4 subjects with abnormal findings post-dilatation of pupils on formal Amsler examination, but normal on repeat examination without dilatation.

## 5. Retinal examination (dilated funduscopy)

In all subjects, except those discussed in Part A that proceeded to have fluorescein angiograms, retinal examination was by dilated funduscopy only. Dr Lillicrap performed these examinations on the first group of 33 subjects. For the remaining 62 both Dr Lillicrap and Major Brown examined and discussed each case, and reached a consensus report for each subject.

A total of 32 (43%) of the tafenoquine subjects, and 6 (29%) of mefloquine subjects had findings reported at the 6 month examination. These examinations were all reported as normal at baseline.

The predominant finding was a granularity/pigmentation of the RPE. Although the degree of pigmentation in the macula is very variable, any irregularity in this pigmentation was recorded. A total of 17 tafenoquine and 2 mefloquine subjects had such findings alone. An additional 9 tafenoquine and 3 mefloquine subjects had these findings but were considered by the ophthalmologists to be within normal limits. In a further 5 tafenoquine subjects such changes in the RPE were accompanied by hard drusen; in one tafenoquine subject only hard drusen were reported. These hard drusen appear as small, yellow, discrete deposits of debris beneath the basement membrane of the RPE. These deposits are thought to be lipid, and although very common after the age of 50 years are not routinely found in such a young population as Australian soldiers. Drusen can be associated with other RPE changes.

Retinal examination	Tafenoquine (%)	Mefloquine (%)
Findings		
Granularity/pigmentation of RPE	17 (23%)	2 (9%)
Granularity/pigmentation of RPE with hard drusen	5 (7%)	0 (0%)
Granularity of RPE but 'within normal limits'	9 (12%)	3 (14%)
Hard drusen only	1 (1%)	1 (5%)
Total subjects with findings	32 (43%)	6 (29%)
Subjects with 'no abnormalities'	42 (57%)	15 (71%)
ALL	74 (100%)	21 (100%)

As such changes in the pigmentation of the RPE are non-specific and the spectrum of what is considered normal is rather subjective, additional investigations are required to further investigate potential retinal pathology. Ten subjects (9 tafenoquine and 1 mefloquine) proceeded to fluorescein angiogram examination (see Part A) on the basis of those with the most pronounced changes in the RPE.

As previously discussed 7 of the 10 angiogram are reported as normal. Of the 3 angiograms with findings (2 tafenoquine, 1 mefloquine) each demonstrates focal pinpoint areas of abnormal hyperfluorescence in the perifoveal region. These abnormalities appear to be at the level of the RPE. Each study demonstrates an abnormality in only one eye. These findings are nonspecific, and the clinical significance is unclear at this stage.

Of note is the fact that given the high % of tafenoquine subjects who developed corneal changes on tafenoquine the ophthalmologists were clearly alerted to a drug effect as they performed the funduscopy. With this knowledge every retinal finding at the 6 month examination has been recorded. The degree to which such vigour was applied at the baseline examination, given a normal cornea, is questionable.

## 6. Correlation of eye changes – tafenoquine subjects

The following table summarises the number of tafenoquine subjects with a primary finding that had associated findings also of potential concern.

For example it could highlight correlation between both granularity/pigmentation of RPE  $\pm$  hard drusen and reductions in colour vision or visual acuity.

Although the numbers are small no obvious correlation is evident.

Primary finding	Associated with			
	Corneal changes	↓ Visual acuity	↓ Colour vision	Granularity/pigmentation of RPE $\pm$ hard drusen
Corneal changes n=65	-	14 (22%)	17 (26%)	22 (34%)
↓ Visual acuity n=17	14 (82%)	-	6 (35%)	3 (18%)
↓ Colour vision n=18	17 (94%)	6 (33%)	-	4 (22%)
Granularity/pigmentation of RPE $\pm$ hard drusen n=22	22 (100%)	3 (14%)	4 (18%)	-
Proceeding to angiogram n=9	9 (100%)	1 (11%)	3 (33%)	8 (89%)

## 7. Summary and next steps

Of 95 subjects dosed with either tafenoquine (n=74) or mefloquine (n=21) for 6 months there were no clinically significant changes in visual acuity and colour vision, or in visual field testing (assessed by Amsler grid) at 6 months compared to baseline.

A high proportion (88%) of tafenoquine subjects, but no mefloquine subjects, developed corneal deposits (a vortex keratopathy). This is seen with several other drugs, and is not unexpected given the nature of this compound. Such changes are expected to be totally reversible. All subjects were asymptomatic when this was first reported, have remained so, and are being followed to confirm reversibility of this phenomenon.

On dilated funduscopy retinal findings were reported in 32 (43%) and 6 (29%) of tafenoquine and mefloquine subjects respectively. The predominant finding was granularity/pigmentation of the retinal pigment epithelium (RPE); a smaller number had hard drusen. Although not reported at baseline in any of these subjects, given the high proportion of tafenoquine subjects who developed corneal changes on tafenoquine the ophthalmologists were clearly alerted to a drug effect as they performed the funduscopy. The degree to which such vigour was applied at the baseline examination, given a normal cornea, is questionable. What is also unclear is the background rate of such findings in a normal age-matched population.

To date 10 of the subjects (9 tafenoquine and 1 mefloquine) with retinal findings on funduscopy proceeded to have fluorescein angiogram. A further 8 angiogram have not yet been performed. No fluorescein angiograms were performed on any subject before commencing study drug. Of these 10 angiograms 3 are reported as abnormal. Of these, 2 (one tafenoquine and one mefloquine) have pinpoint areas of hyperfluorescence only; the third also demonstrates leakage of fluorescein, and is clearly abnormal (a tafenoquine subject).

In the absence of baseline angiogram data it is not yet possible to determine the relevance of these structural changes to either retinal function or administration of study drug. External advice is being sought as to how to better characterise, and determine the clinical significance, of these retinal findings. This is likely to involve additional assessments on all 95 subjects as they return for follow up in the next weeks. Extended follow up may be necessary. Repeat angiograms will also be performed on the three subjects discussed above.

At this stage we believe that results from additional investigations and expert discussions are needed before any decisions can be made regarding follow up of patients. As additional data becomes available this position will be reviewed.

As further information becomes available, follow-up reports will be provided

**PART C****LUNG FUNCTION TESTS****1. DLCO measurements**

As a possible marker for an effect of phospholipidosis on the lung each subject had a DLCO recorded at baseline and at 6 months. This value was converted into a % of predicted DLCO for each subject (according to their height and age). The changes in these % predicted DLCOs from baseline to 6 months are tabulated below.

The creation of methaemoglobin, with the resulting reduction in binding capacity of blood (for oxygen and/or carbon monoxide), would be expected to effect the parameter of DLCO. However, there is no published literature on this and external experts are being consulted over a possible suitable correction factor. The effect on measured DLCO is expected to be minor in the tafenoquine group given the low levels of methamoglobin seen on drug

	<b>TQ (n=74)</b>	<b>MQ (n=21)</b>
<b>Baseline DLCO as % of predicted for each subject</b>		
Mean	105.6%	107.0%
Median	101.0%	104.0%
Range	80.0% to 163.0%	80.0% to 131.0%
<b>DLCO at 6 mths as % of predicted for each subject</b>		
Mean	97.3%	98.6%
Median	96.0%	101.0%
Range	74.0% to 129.0%	66.0% to 120.0%
<b>Change in % predicted DLCO at 6 mths</b>		
Mean	-8.9%	-8.7%
Median	-7.0%	-9.0%
Range	-36.0% to +11.0%	-27.0% to +15%

In contrast to the initial Safety Report where the reported tafenoquine (n=26) and mefloquine (n=7) mean changes were -7.1% (range: -20 to 9%) and -3.0% (range: -15 to 4%) respectively these data are more reassuring.

These mean changes are not considered clinically significant and the effect of 6 months dosing with tafenoquine appears very similar to that of mefloquine. All chest X-rays are reported as normal.

## 2. Summary and next steps

Preliminary findings from the initial group of 33 subjects, after 6 months dosing of tafenoquine or mefloquine, showed a slightly larger fall in % predicted  $D_LCO$  values in tafenoquine subjects (-7.1%) compared to the comparator mefloquine group (-3.0%). Combined data from an additional 62 subjects are more reassuring with similar falls (-8.9%, -8.7%) in % predicted  $D_LCO$  across both groups.

The range of changes was wide in both treatment groups. Those subjects at the extremes of each range will have repeat  $D_LCO$  examinations at a follow up in the next few weeks. No additional assessments such as CT scanning, further chest X-rays, and use of experimental serum markers is proposed.

As further information becomes available, follow-up reports will be provided



## Appendix A

### Safety Report of 9-May 2001

#### CONFIDENTIAL

#### Letter to the Regulatory Authorities

#### TO WHOM IT MAY CONCERN

Dear Sirs

#### **Summary**

The purpose of this Safety Report is to inform Regulatory Agencies, Ethics Committees and Investigators of preliminary safety findings related to the monitoring for the effects of phospholipidosis in a Phase III Tafenoquine clinical study.

These data are from a subset of subjects ( $n = 33/99$ ) in a Phase III study (Study 252263/033) investigating the safety, tolerability and effectiveness of tafenoquine in the prophylaxis of malaria in non-immune Australian soldiers deployed to East Timor.

Ophthalmological (corneal examination, visual acuity, visual field) and lung function testing (diffusing capacity of carbon monoxide –  $D_LCO$ ) data are presented on the first 33 soldiers within this subset, 26 of whom were receiving tafenoquine and 7 of whom were receiving mefloquine. After 6 months weekly dosing corneal changes (a vortex keratopathy) have been seen in 25 of 26 tafenoquine subjects, but in none of the 7 mefloquine subjects. Amsler grid examinations suggest mild visual field changes in 4 tafenoquine subjects, but not mefloquine subjects. Minor visual acuity changes are reported across both treatment groups. All examinations were normal at baseline.

The changes considered to be clinically significant are the 4 tafenoquine subjects with Amsler grid changes (subjects 17, 18, 22, 24 in Appendix C), and single tafenoquine subject (subject 14) with more central corneal changes in a Lasik-corrected eye and a reduction in visual acuity. These have been reported as SAEs by the Investigator.

Similar corneal changes (vortex keratopathy) have been observed with other cationic amphiphilic agents. However given the requirement to establish the reversibility of these changes off study drug, and more fully understand the associated visual field and visual acuity changes, GlaxoSmithKline have voluntarily suspended all tafenoquine dosing across both the adult and paediatric programmes.

## 1. Background to the compound

Tafenoquine is a new 8-aminoquinoline antimalarial drug being co-developed by GlaxoSmithKline, and the US Army Medical Research and Materiel Command. It is a synthetic analogue of primaquine and has been shown to be effective against plasmodial infections *in vitro*, and also *in vivo* during early phase clinical studies.

The compound is currently in Phase III development for the prophylaxis of all forms of malaria in subjects age 12-65 years. The dosing regimen is 200mg daily for 3 days, followed by 200mg once weekly whilst in a malaria endemic area.

A paediatric development programme has just commenced with a Phase II dose-escalation study to evaluate safety, tolerability and population pharmacokinetics of tafenoquine in children aged 6 months to 14 years infected with *P. vivax*.

## 2. Pre Clinical Findings

Phospholipidosis was observed in animal toxicology studies. Phospholipidosis is common to this type of compound (cationic amphiphilic) and is characterised by the excessive accumulation of intracellular phospholipids. Effects seen in animal studies were principally manifested in the lung with accumulation of foamy macrophages and back-up of surfactant, although any tissue in the body may be affected. A full analysis of the pre-clinical findings and background to phospholipidosis is given in Appendix B.

Reversibility of the effects of tafenoquine administration was assessed during a 13-week off-dose period following 13 weeks treatment (rats and dogs). Lung effects (oedema, proteinosis, inflammation, foamy macrophages) were completely reversed.

## 3. Phospholipidosis monitoring data from Phase I

Lung monitoring in a Phase I study in healthy volunteers (n=24) did not reveal any clinically significant changes on lung function testing. This was a double blind placebo controlled study to evaluate the safety and tolerability of weekly doses of tafenoquine. Three groups of 12 [REDACTED] received 10 weekly doses of 200mg, 400mg or 600mg tafenoquine or placebo. In each group 8 received active drug and 4 received placebo

Of note is that this study did not include the 3 day loading dose regimen adopted in subsequent clinical studies, and the Phase III weekly prophylaxis regimen is 200mg tafenoquine. Full details of the phospholipidosis monitoring are given in Appendix D.

#### 4. Phospholipidosis monitoring data from Phase III: Study 252263/033

##### 4.1 Study 033

Study 033 is a randomised, double-blind, comparative study to evaluate the safety, tolerability and effectiveness of tafenoquine and mefloquine for the prophylaxis of malaria in non-immune Australian soldiers deployed to East Timor.

A total of 652 subjects were randomised in October 2000 in a 3:1 ratio to either tafenoquine (approximately 490 subjects) or mefloquine (approximately 160 subjects) and then deployed into East Timor for 6 months peace-keeping duties. Having completed this period of deployment and study medication the soldiers are now coming out of area and returning to Australia.

Following expert consultation a monitoring programme was devised to further assess the potential of tafenoquine to induce phospholipidosis in humans in Study 033 that would focus on a subset of approximately 100 subjects. Non-invasive techniques were chosen for monitoring in Study 252263/033 that focus on three targets: lung, eye and peripheral lymphocytes.

This subset had assessments performed at baseline, before deployment, and at 6 months as they were leaving the endemic area and having completed study medication. The techniques chosen are as outlined below – i.e. eye examinations, lung function testing, and collection of blood samples for EM examination of peripheral lymphocytes. In view of the nature and location of this study it was not possible logistically to select either a larger group of subjects, or perform more frequent examinations.

##### LUNG

###### 1. Lung function tests

- Diffusing capacity of carbon monoxide –  $D_LCO$ .

This is a measurement of carbon monoxide transfer from inspired gas to pulmonary capillary blood. Many processes are associated with alterations in  $D_LCO$ , with decreases seen in obstructive lung disease, interstitial lung disease (e.g. amiodarone pulmonary toxicity associated with phospholipidosis) and pulmonary involvement in systemic diseases.

- Forced expiratory volume in 1 second -  $FEV_1$

###### 2. Chest X-rays

##### EYE

1. Slit-lamp examination of eye, eye-lids, cornea, retina and associated structures
2. Amsler grid examination of visual fields
3. Visual acuity testing
4. Colour vision assessment

## PERIPHERAL BLOOD LYMPHOCYTES

Electron microscopic examination of peripheral lymphocytes for the presence of lamellated inclusion bodies.

### *4.2 Phospholipidosis Findings*

Initial review of these data showed a large proportion of subjects in the preliminary group to have corneal deposits, and a much smaller number of potentially significant visual field changes. As a result, these data were unblinded on 1-May-2001 via the Independent Data Monitoring Committee that oversees the adult programme to assist in data interpretation and subsequent follow-up activities. The data are summarised below and presented in full in the Appendix C. In order to maintain the blind, data are not presented with individual patient identifiers.

## EYE EXAMINATIONS

### *Corneal changes*

Of the 26 tafenoquine subjects 25 have corneal deposits with a vortex pattern. All subjects were asymptomatic. No corneal changes were seen with any of the 7 mefloquine subjects. On slit lamp examination the appearance of these changes is that of yellowish brown corneal epithelial deposits, symmetrical and bilateral in a vortex pattern below the pupil with a swirl outward and in all cases sparing the limbus. In one subject (subject 14 in Appendix C) who has had a Lasik correction of myopia to one eye this epithelial whorl was centrally placed over the optical axis in the eye that has had the previous Lasik whilst, in the unoperated eye it was in the normal position, i.e. below the optical axis.

### *Visual acuity*

Of the 26 tafenoquine subjects 11 had minor changes in visual acuity on formal testing (2 decreased, 9 increased). Only one change is considered clinically significant: a reduction from 6/6, 6/6 to 6/9, 6/12.

Of the 7 mefloquine subjects 2 had minor changes in visual acuity (one decreased, one increased). Only one of these however, is considered to be clinically significant which was a reduction from 6/6, 6/6 to 6/6, 6/9. No subject reported visual symptoms.

### *Amsler grid testing – visual fields*

Of the 26 tafenoquine subjects 4 had mild visual field changes on testing with the Amsler grid (Question 3). These formal Amsler assessments were performed post-dilatation of pupils which is reported by the Ophthalmologist to have affected the results. No such changes were reported in the mefloquine subjects. Amsler screening tests pre-dilatation of pupils were reported as normal in all 33 subjects examined. There were no macular deposits in any subject. Formal Amsler assessments without mydriatics are to be repeated on these 4 tafenoquine subjects during the week commencing 7-May-2001.

The changes considered to be clinically significant are the 4 tafenoquine subjects with Amsler grid changes (subjects 17, 18, 22, 24 in Appendix C), and single tafenoquine subject (subject 14) with more central corneal changes in a Lasik-corrected eye and a reduction in visual acuity. These have been reported as SAEs by the Investigator.

## LUNG FUNCTION TESTS

### *D<sub>L</sub>CO measurements*

The changes in % predicted D<sub>L</sub>CO from baseline to 6 months have been reported as follows:

Tafenoquine (n=26)	Mean: -7.1% Range: -20 to 9%
Mefloquine (n=7)	Mean: -3.0% Range: -15 to 4%

The single tafenoquine subject who had no corneal changes also had a D<sub>L</sub>CO difference of zero. The small numbers in the two groups make any statistical comparison difficult. The clinical significance at this magnitude of change is also unclear. It should be noted that these data have not been corrected for methaemoglobinaemia which is known to depress D<sub>L</sub>CO measurements and has been seen with Tafenoquine. Data on this correction factor are being sought.

## 5. Study Withdrawals and SAEs in Study 033

A total of 14 of the 652 subjects withdrew from the Study 252263/033. None of the reasons for withdrawal involved either visual problems or respiratory problems. In only 3 subjects was the reason for withdrawal considered drug related: one case each of recurrent abdominal pain, depression and rash. These data remain blinded at this stage.

A total of 27 SAEs in 26 subjects have been reported in Study 252263/033. Twelve involved the gastrointestinal system (abdominal pain, diarrhoea, gastro-enteritis) which included 3 cases of proven *Entamoeba histolytica* and 1 case of *Cyclospora* spp. infection. There were 2 cases each of gun shot wounds, in-grown toenails, venomous bites and epididymo-orchitis. In only 2 subjects was the SAE considered possibly related/suspected related to study drug. The first was repeated abdominal pain shortly after dosing which led to study withdrawal, the second was a case of respiratory tract infection. A chest X-ray showed reticular nodular infiltrate, bilaterally consistent with an interstitial pneumonitis, probably viral or atypical in aetiology. The investigator considered this to be serious because the subject was hospitalised, and possibly related to study medication as a drug reaction was unlikely but still possible.

Of note is the fact that *unblinded* SAE and withdrawal data from the Study 252263/033 were reviewed on two occasions during the study via the Independent Data Monitoring Committee that oversees the adult programme. No concerns were raised.

On reviewing 'VISION' associated events across the tafenoquine clinical programme there were two further relevant reports i) conjunctivitis (which was reported as a sign/symptom of

respiratory tract infection in the SAE discussed above, and ii) blurred vision (which was reported a sign/symptom of viraemia and in association with respiratory tract symptoms, sore throat, severe headache and a rigor. On a similar review of 'RESPIRATORY SYSTEM' there were four cases of pharyngitis and five cases of pneumonia.

## **6. Other cationic amphiphilic agents – effects in humans**

Most data relate to long term use of amiodarone and chloroquine.

In the case of amiodarone corneal changes occur in 75-100% of treated individuals usually 1-4 months after commencing therapy and are dose and duration related. A small proportion (up to 10%) may get visual symptoms such as haloes or blurred vision. These changes are reversible off therapy (with a mean time to resolution of approximately 3 months) and alone are not an indication to reduce the dose or discontinue amiodarone therapy.

Corneal deposits are also seen with long term chloroquine therapy. These appear to be less related to dose or duration of treatment, but as with amiodarone are reversible off therapy. Of far more concern is a chloroquine retinopathy, with associated visual field and colour vision changes, and macular pigmentation progressing to the classical bull-eye maculopathy. These changes are irreversible. The mechanism is unclear - although it may reflect the affinity of chloroquine for melanin and a damaging effect on retinal cells rather than a direct phospholipidosis effect. However, lamellated inclusion bodies have been seen in retinal ganglion cells.

Pulmonary toxicity is well described with amiodarone and potentially fatal in a minority of cases. The toxicity may involve a hypersensitivity pneumonitis or a direct toxic effect leading to an interstitial pneumonitis. Features of phospholipidosis are seen in the lung (foamy macrophages etc.) in most cases with toxicity but also in many cases without obvious toxicity. Pulmonary toxicity is an indication to reduce dose or discontinue amiodarone therapy and establish reversibility. Reductions in  $D_LCO$  of at least 15% are considered to be a useful predictor of amiodarone-induced toxicity.

## 7. Actions

### 7.1 Voluntary suspension of dosing in Ongoing Clinical Studies

Given the requirement to establish the reversibility of these changes off study drug, and associated visual field and visual acuity changes, GlaxoSmithKline have voluntarily suspended all tafenoquine dosing across both the adult and paediatric programmes pending further investigation of the findings.

Only three clinical studies were actively dosing:

- 1) this adult Phase III study - Study 252263/033
- 2) a paediatric Phase II study – Study 252263/036, a multicentre, randomised, active-controlled, open-label, dose-escalation study to evaluate the safety, tolerability and population pharmacokinetics of tafenoquine in children (6 months to 14 years) infected with *P. vivax* and to assess the potential of tafenoquine to prevent relapse of *P. vivax*.
- 3) an open label compassionate use study - Study 252263/046, in recurrent *P. vivax*.

The final cohort of approximately 180 soldiers in Study 252263/033 that were about to leave East Timor had their final regular weekly capsule on 29-April 2001. An additional capsule due to be given to all soldiers on the day of departure, due 1-May-2001 in this final cohort, was withheld.

At the time of the voluntary suspension only one child had been enrolled into the paediatric study and had received only a single tafenoquine capsule at a dose of 1.5mg/kg (approximately half the adult dose).

Four subjects in the open label compassionate use study have had their weekly dosing suspended part way through the 8 week treatment regimen.

### 7.2 Follow-up of subjects and additional data not yet available

Results of the monitoring assessments for the remainder of this subset of 99 (i.e. approximately 65 subjects) are expected to be available the week of 14-May-2001.

In view of the uncertainty around the visual field and visual acuity reports, those 6 subjects with Arnsler grid changes or clinically significant visual acuity changes will be re-examined as a matter of urgency, and are planned for the week commencing 7-May-2001.

The electron micrographs of peripheral lymphocytes will not be available until June/July-2001.

Plans are being formulated to follow-up subjects in this study to establish reversibility of corneal changes with follow-up assessments initially being scheduled for 2 weeks and 2-3 months after the initial examination. Data from a single tafenoquine subject (subject 8 in Appendix C) have already established complete reversibility of early corneal changes after only 8 days. Additional ophthalmological and respiratory assessments are being considered.

In addition, early study withdrawals will be examined, as will control subjects administered tetracycline for 6 months whilst in East Timor to exclude any environmental effect.

Once all the data are available from this study, consideration will be given to follow-up of subjects in previous clinical studies. In the only completed Phase III adult study (SB 252263/030) which commenced in April-2000 in Kenya only 5 subjects remained in the study at 6 months (study completion). All dosing was completed by October-2000, i.e. subjects are at least 6 months off drug. In the Phase II programme, long term weekly dosing was administered in two studies in Kenya and Ghana for up to 12 weeks. Dosing was completed in December-1998, i.e. subjects are at least 28 months off drug.

## 8. Overall Conclusions

Preliminary findings from a group of 33 Australian troops after six months of weekly tafenoquine prophylaxis have shown eye findings affecting the cornea and possibly the visual fields. The corneal deposits have been detected at an incidence of >95% in tafenoquine treated subjects and are almost certainly the result of drug-induced phospholipidosis. Experience with other cationic amphiphilic drugs suggest that this will be a reversible phenomenon. Other eye findings include visual field effects but it is unclear at the moment whether these may be related to use of mydriatics before examination and imminent follow-up will help clarify this issue.

Another possible indicator of phospholipidosis in the lung,  $D_LCO$ , shows a slightly larger fall in predicted values in tafenoquine subjects (-7.1%) compared to the comparator mefloquine group (-3.0%), but the subject numbers are small and clinical significance at this stage is unclear. Data from an additional 66 subjects plus correction for methaemoglobinaemia should add value to these observations.

In considering these data GlaxoSmithKline have voluntarily suspended further administration of study drugs in their ongoing adult and paediatric development programs. Further follow-up information is being gathered on this subset of 99 Australian troops being investigated for markers of phospholipidosis. Additional investigations to those originally planned will be considered and after expert consultation a proposal for further follow-up will be developed.

As further information becomes available, follow-up Safety Reports will be provided.



## Appendix B

### Animal toxicology studies: phospholipidosis

Key target tissue effects in general toxicology studies of tafenoquine of up to 6 months and 1 years duration in rats and dogs respectively were oxidative changes in red cell elements of blood and findings indicative of phospholipidosis (foamy macrophage accumulation, lamellar inclusion bodies in alveolar macrophages and type II pneumonocytes, and eosinophilic material in alveoli), which were manifested principally in lung. Hepatic findings (including increased weight, small increases in plasma enzyme markers, subacute inflammation and fatty changes) may reflect pathophysiological responses to either or both anaemia or altered phospholipid accumulation.

The approximate overall no-effect dose in rats was 0.5 mg/kg/day (6-month study) and in dogs was 0.1 mg/kg/day (1-year study). In 8-week studies, these doses were shown to be associated with plasma  $AUC_{(0-1 \text{ week})}$  values of 6660 ng.h/mL in rats and 6840 ng.h/mL in dogs (sexes combined). Calculation of  $AUC_{(0-1 \text{ week})}$  values reflect a clinical regimen of a single 200 mg dose of tafenoquine once weekly. When measured on the same basis, systemic exposures at the no-effect doses in both rat and dog were approximately 12% of the AUC in man.

Lung changes were observed in rats and dogs in all repeated dose studies. Findings increased in severity with both dose and period of tafenoquine administration. The common factor in lung pathology in both species was an increase in foamy alveolar macrophages. In some studies this was accompanied by the presence of eosinophilic material in alveoli, which was a more prominent feature after shorter rather than longer periods of dosing. Conversely, associated inflammation appeared to be more severe with longer duration of dosing. Interstitial fibrosis and/or interstitial thickening was described in the off-dose groups on the 13-week studies, but it is not entirely clear whether there was, or was not, a true interstitial inflammatory response, or whether the interstitial changes described were primary or reactive to events in the alveoli.

The lung findings are indicative of phospholipidosis, arising as a consequence of inhibition of macrophage ability to metabolise surfactant. This leads to accumulation of foamy macrophages and back-up of surfactant, with poor clearance of fluid in alveoli, suggesting that the eosinophilic material in alveoli may be an effect secondary to macrophage malfunction.

Structurally, tafenoquine has cationic amphiphilic characteristics, according to its potential to cause phospholipid accumulation. Furthermore, examination by transmission electron microscopy of the lungs from dogs given 4 mg tafenoquine/kg/day for 8 weeks showed alveolar macrophages containing lamellated inclusion bodies and numerous secondary lysosomes. Type II pneumonocytes were enlarged and also contained lamellated inclusion bodies. Similar inclusions were observed in all macrophages and in up to 10% of the lymphocytes in mesenteric lymph nodes from the same animals. Numbers of single or multiple dense inclusion bodies within up to 60% of the lymphocytes were increased concurrently. No treatment-related ultrastructural changes were evident in white blood cells from the peripheral circulation.

The lamellated inclusion bodies observed in lung and lymph node are consistent with those reported in the literature as characteristic of phospholipidosis.

Some cationic amphiphilic agents can cause lipid deposits in the corneal epithelial cells. however, direct and/or indirect ophthalmoscopy in 13- & 26-week studies in rat, and 28-day, 13-week and 52-week studies in dog did not reveal any tafenoquine-related corneal opacities or retinal effects.

Reversibility of the effects of tafenoquine administration was assessed during a 13-week off-dose period following 13 weeks' treatment of rats and dogs . Lung effects (oedema, proteinosis, inflammation, foamy macrophages) reversed, although focal and subpleural chronic inflammation (interstitial fibrosis, mononuclear cell infiltration) was evident at the off-dose necropsies, and ascribed to the process of resolution of the earlier events



TABLE 1. PRE- AND POST-OPERATIVE DATA						
Subject	Pre-Operative Visual Acuity (V/m)	Post-Operative Visual Acuity (V/m)	Baseline D (D)	Post-Operative D (D)	AD (D)	Comments
8	YES	Pre 6/6, 6/6 Post 6/6, 6/6	135	120	-15	Early corneal deposits.
9	YES	Pre 6/6, 6/6 Post 6/6, 6/6	100	105	+5	Early corneal swirl deposits, minimal pigmented
10	YES	Pre 6/6, 6/6 Post 6/6, 6/6	104	100	-4	Minimal linear epithelial whirl
11	YES	Pre 6/4, 6/4 Post 6/5, 6/5	124	107	-17	Corneal subepithelial deposits.
12	YES	Pre 6/6, 6/6 Post 6/5, 6/5	112	102	-10	Early corneal changes.
13	YES	Pre 6/6, 6/6 Post 6/5, 6/5	120	111	-9	Minimal linear pigmented subepithelial deposits.
14	YES	Pre 6/7.5, 6/6 Post 6/9, 6/12	81	76	-5	Central whirl - Right and whirl inflows left. Previous Lasik scar.
15	NO	Pre 6/6, 6/6 Post 6/5, 6/5	117	117	0	

PATIENTS WITH PREVIOUS MALARIA RELATED SUBURCES						
Subject	A7 Kerning (y/n)	A7 Vism num, (y/n)	Baseline DCO (% preferred)	Baseline DCO (% preferred)	A1, CO (% preferred)	Comment
16	YES	= Pre 6/6, 6/6 Post 6/6, 6/6	124	109	-15	Minimal epithelial whirl
17	YES	= Pre 6/6, 6/6 Post 6/6, 6/6	108	92	-16	Q3(Amsler), mild epithelial whirl
18	YES	= Pre 6/6, 6/6 Post 6/6, 6/6	103	98	-5	Q3(Amsler), linear epithelial whirl
19	YES	= Pre 6/6, 6/6 Post 6/6, 6/6	120	103	-17	Minimal epithelial whirls
20	YES	+ Pre 6/6, 6/6 Post 6/5, 6/5	126	109	-17	Minimal linear epithelial whirl
21	YES	= Pre 6/6, 6/6 Post 6/6, 6/6	109	107	-2	Mild corneal whirl.
22	YES	= Pre 6/6, 6/6 Post 6/6, 6/6	102	109	+7	Q3(Amsler) mild epithelial whirl deposits.
23	YES	+ Pre 6/6, 6/6 Post 6/5, 6/5	102	95	-7	Linear whirl bilaterally, ? yellowed deposit.

Subject	A (Keratopathy) (V/D)	A Visual (V/D)	Baseline Dp(CO) (% predicted)	amblyopia (C) (% predicted)	A Dp(CO) (%)	Comment
24	YES	= Pre 6/6, 6/6 Post 6/6, 6/6	99	93	-6	Q3 (Amster) whirls bilaterally, ? slight deposit around macular.
25	YES	= Pre 6/6, 6/6 Post 6/6, 6/6	104	92	-12	Whirl, left > right.
26	YES	=* Pre 6/6, 6/6 Post 6/6, 6/6	100	87	-13	Linear corneal verticillata? * with glasses

MULTI-OBJECTIVE TREATMENT STUDIES						
Subno	A Neuropathy (6/6)	A Visual Acuity (6/6)	Baseline DCO (% predicted)	6mo DCO (% predicted)	12mo DCO (% predicted)	Comments
27	NO	Pre 6/6, 6/6 Post 6/6, 6/9 =	128	120	-8	Mild myopia unrelated to antimalarial treatment
28	NO	Pre 6/6, 6/6 Post 6/6, 6/6 =	105	108	+3	
29	NO	Pre 6/6, 6/6 Post 6/6, 6/6 =	104	108	+4	
30	NO	Pre 6/6, 6/6 Post 6/6, 6/6 =	118	120	+2	
31	NO	Pre 6/6, 6/6 Post 6/6, 6/6 =	99	98	-1	
32	NO	Pre 6/6, 6/6 Post 6/6, 6/6 =	100	94	-6	
33	NO	Pre 6/6, 6/6 Post 6/6, 6/6 =	123	108	-15	

## Appendix D – Phospholipidosis monitoring in Phase I

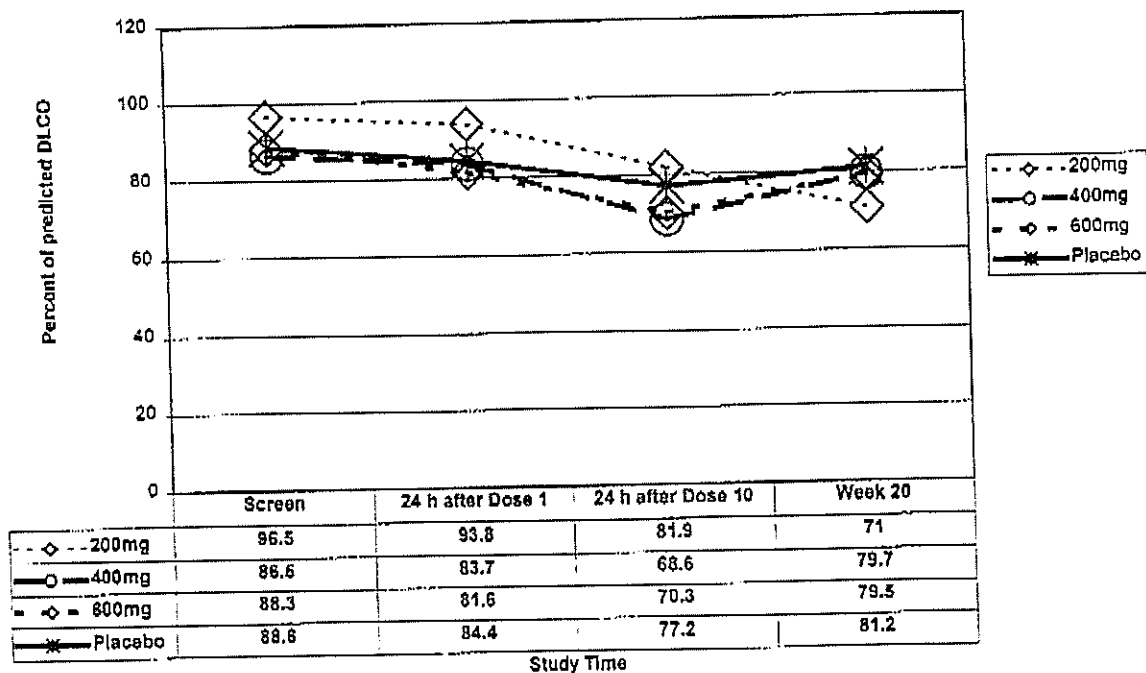
Prior to Phase III phospholipidosis monitoring had been limited to a single Phase I study where no signal was detected. This was a double blind placebo controlled study to evaluate the safety and tolerability of weekly doses of tafenoquine. Three groups of 12 healthy volunteers (male and female) received 10 weekly doses of 200mg, 400mg or 600mg tafenoquine or placebo. In each group 8 received active drug and 4 received placebo.

Of note this study did not include the 3 day loading regimen adopted in subsequent clinical studies, and the Phase III weekly prophylaxis regimen is 200mg tafenoquine.

Lung function testing (FVC, FEV<sub>1</sub>, D<sub>L</sub>CO) was performed on all subjects at baseline, after the final weekly dose (week 10), and at a follow-up visit 10 weeks later (week 20).

There was a broad range of values for individual lung function tests, but none of the values were judged to be clinically significant. The D<sub>L</sub>CO data are shown below. The mean change in percentage predicted D<sub>L</sub>CO from baseline to week 10 was -9.8% and -10.2% for tafenoquine (n=22) and placebo (n=11) subjects respectively.

Mean percentage predicted DLCO, corrected for Hemoglobin concentration, in each dosing group and in the group receiving placebo.



No additional monitoring for possible effects of phospholipidosis (e.g. eye examinations) were performed in this study, and no further assessments for phospholipidosis were performed during the remainder of the Phase I and Phase II clinical programme.



**Appendix E – Investigator Letter of 9-May-2001**

***Memorandum***

**To:** Investigators involved in the TAFENOQUINE clinical programme:

Study 252263/033  
Study 252263/032  
Study 252263/029  
Study 252263/036  
Study 252263/046  
Study 252263/030  
Study 252263/042

**From:** GlaxoSmithKline

**Date:** 9-May-2001

**Subject:** Initial IND Safety Report – Tafenoquine (SB 252263, WR 238605)

IND 38,503

AEGIS Numbers:

2001010840-1, 200101842-1, 200101843-1, 200101845-1, 200101848-1

Study 252263/033 ADMEC No. 216/00

A randomised, double-blind, comparative study to evaluate the safety, tolerability and effectiveness of tafenoquine and mefloquine for the prophylaxis of malaria in non-immune Australian soldiers deployed to East Timor

---

In accordance with Regulatory guidelines and GlaxoSmithKline (GSK) policy, we are providing you with a copy of an IND Safety Report, which was recently submitted to all Regulatory Authorities concerned with the TAFENOQUINE clinical programme. This is a report of ocular changes which occurred in patients participating in the above mentioned study.

Similar corneal changes (vortex keratopathy) have been observed with other cationic amphiphilic agents. However given the requirement to establish the reversibility of these changes off study drug, and associated visual field and visual acuity changes, GlaxoSmithKline have voluntarily suspended all tafenoquine dosing across both the adult and paediatric programmes. This position will be reassessed when further data becomes available. All dosing with TAFENOQUINE in any active clinical study must therefore stop immediately if it has not already done so.

In accordance with Good Clinical Practice, please promptly inform your Ethics Committee/Investigational Review Board, co-investigators and study co-ordinators of its content. Please file this letter with your Investigator Brochure/Study File.

### Summary

After 6 months weekly dosing corneal changes (a vortex keratopathy) have been seen in 25 of 26 tafenoquine subjects, but in none of the 7 mefloquine subjects. Amsler Grid examinations suggest mild visual field changes in 4 tafenoquine subjects, but not in mefloquine subjects. Minor visual acuity changes were reported across both treatment groups. All examinations were normal at baseline. The changes considered to be clinically significant are the 4 tafenoquine subjects with Amsler Grid changes (subjects 17, 18, 22, 24 in Appendix B), and single tafenoquine subject (subject 14) with more central corneal changes in a Lasik-corrected eye and a reduction in visual acuity. These have been reported as SAEs by the Investigator.

These subjects had received 6 months study medication with TAFENOQUINE at a dose of 200mg once a week and are part of a subset of subjects in this study that are being monitored for possible effects of phospholipidosis due to observations in animal toxicology studies.

To date over 4000 patients have been enrolled in TAFENOQUINE clinical studies, and approximately 2900 have received active medication. These are the first serious events reported to GSK of eye problems in patients participating in a TAFENOQUINE clinical study.

### Pre Clinical Findings

Phospholipidosis was observed in animal toxicology studies. Phospholipidosis is common to this type of compound (cationic amphiphilic) and is characterised by the excessive accumulation of intracellular phospholipids. Effects seen in animal studies were principally manifested in the lung with accumulation of foamy macrophages and back-up of surfactant, although any tissue in the body may be affected. Further details of the studies in which this effect were seen are given in Appendix A of the safety report.

Some cationic amphiphilic agents can cause lipid deposits in the corneal epithelial cells. However, direct and/or indirect ophthalmoscopy in animal studies (rat and dog) did not reveal any TAFENOQUINE-related corneal opacities or retinal effects.

Reversibility of the effects of TAFENOQUINE administration was assessed during a 13-week off-dose period following 13 weeks treatment (rats and dogs). Lung effects (oedema, proteinosis, inflammation, foamy macrophages) were completely reversed.

## Clinical Findings

Lung monitoring in a Phase I study in healthy volunteers (n=24) did not reveal any clinically significant changes on lung function testing. This was a double blind placebo controlled study to evaluate the safety and tolerability of weekly doses of tafenoquine. Three groups of 12 healthy volunteers (male and female) received 10 weekly doses of 200mg, 400mg or 600mg tafenoquine or placebo. In each group 8 received active drug and 4 received placebo

Of note is that this study did not include the 3 day loading dose regimen adopted in subsequent clinical studies, and the Phase III weekly prophylaxis regimen is 200mg tafenoquine.

Following expert consultation a monitoring program was devised to assess the potential of TAFENOQUINE to induce phospholipidosis in humans. Non-invasive techniques were chosen for Study 252263/033 that focus on three targets: lung, eye and peripheral lymphocytes.

Preliminary data from the 33 subjects within the subset of 99 being monitored for phospholipidosis effects are now available. These subjects were assessed at baseline before any study medication, and after 6 months weekly dosing. All examinations were reported as normal at baseline.

On post-study examination of the eyes 25 of 26 TAFENOQUINE subjects had corneal changes. The appearance of these changes is that of yellowish brown corneal epithelial deposits, symmetrical and bilateral in a vortex pattern below the pupil with a swirl outward and in all cases sparing the limbus. All subjects were asymptomatic. No changes were observed in the 7 mefloquine subjects. This appearance is consistent with that observed with other cationic amphiphilic agents given long term, e.g. amiodarone, chloroquine.

In addition to these corneal changes, in 4 TAFENOQUINE subjects there were mild visual field changes on formal Amsler Grid testing. However the interpretation of these results are complicated by prior use of a mydriatic agent. These assessments are in the process of being repeated. All subjects were asymptomatic. Amsler changes were not observed in the mefloquine subjects.

Minor visual acuity changes were also reported post-study. Of the 26 TAFENOQUINE subjects 12 had changes (3 decreased, 9 increased). Only one change is considered clinically significant: a reduction from 6/6, 6/6 to 6/9, 6/12. Of the 7 mefloquine subjects 2 had minor changes in visual acuity (one decreased, one increased). Only one of these however, is considered to be clinically significant which was a reduction from 6/6, 6/6 to 6/6, 6/9. No subject reported visual symptoms or altered acuity.

The four TAFENOQUINE subjects with corneal changes and possible Amsler Grid changes, and the single TAFENOQUINE subject with corneal changes and clinically significant reduction in visual acuity have been reported by the Investigator as Serious Adverse Experiences.

In the case of amiodarone these corneal changes occur in 75-100% of subjects, usually 1-4 months after commencing therapy and are dose and duration related. A small proportion (up to 10%) may display symptoms such as haloes or blurred vision. These changes are reversible off therapy (with a mean time to resolution of approximately 3 months) and alone are not an indication to reduce the dose or discontinue amiodarone therapy.

Corneal deposits are also seen with long term chloroquine therapy. These appear to be less related to dose or duration of treatment, but as with amiodarone are reversible off therapy.

An association between TAFENOQUINE study medication and corneal changes is suspected given the nature of the compound, but is expected to be entirely reversible off therapy.

Additional monitoring data, follow-up on these 33 subjects, and data from the remainder (approximately 66) of this subset of subjects is planned and will provide useful information and help to clarify this issue. When this additional information is available we will update you of the position.

## Appendix F

Appendix F: List of individual subjects with eye findings at 6 months including change from baseline

Treatment ID	Coded ID	Visual Acuity at 6 mths	Change in Visual Acuity	Change in Colour Vision	Screening Amsler at 6 mth	Formal Amsler at 6 mth	Corneal Changes	Macula at 6 months	Flourescein angiogram at 6 mths	Comments
A	1	6/4, 6/4	Improved (+)	No change	Normal	Normal	Changes	Granularity/pigmentation of RPE	Not performed	Screening Amsler Q5: bottom of Chart waving of lines
	2	6/4, 6/4	Improved (+)	3 colour plates worse than baseline	Abnormal	Normal	Changes	Normal	Not performed	
	3	6/5, 6/5	Improved (+)	1 colour plate better than baseline	Normal	Normal	Changes	Normal	Not performed	
	4	6/5, 6/5	No change	1 colour plate worse than baseline	Abnormal	Normal	Changes	Granularity/pigmentation of RPE	Not performed	Screening Amsler Q5: generalised waving of lines
	5	6/6, 6/6	Reduced (-)	No change	Normal	Normal	Changes	Normal	Not performed	
	6	6/5, 6/5	Improved (+)	No change	Normal	Normal	Changes	Normal	Not performed	Old corneal scar right eye
	8	6/4, 6/4	No change	1 colour plate worse than baseline	Normal	Normal	Changes	Normal	Not performed	
	9	6/5, 6/5	Improved (+)	2 colour plates worse than baseline	Normal	Normal	Changes	Normal	Not performed	
	10	6/5, 6/5	Reduced (-)	2 colour plates worse than baseline	Normal	Normal	Changes	Normal	Not performed	

03 JUL 2001

A = Treatment A: TAFENOQUINE 200MG 3 DAYS FOLLOWED BY 200MG WEEKLY  
B = Treatment B: MEFLOQUINE 250MG 3 DAYS FOLLOWED BY 250MG WEEKLY

Appendix F: List of individual subjects with eye findings at 6 months including change from baseline

Treatment ID	Coded ID	Visual Acuity at 6 mths	Change in Visual Acuity	Change in Colour Vision	Screening Amsler at 6 mth	Formal Amsler at 6 mth	Corneal Changes	Macula at 6 months	Fluorescein angiogram at 6 mths	Comments
A	11	6/5, 6/5	No change	No change	Normal	Normal	Changes	Granularity/pigmentation either within normal limits, or abnormal, plus drusen	Granularity/pig Not performed	
	12	6/5, 6/5	Reduced (-)	No change	Normal	Normal	Changes	Granularity/pig Not performed		
	13	6/4, 6/4	Improved (+)	No change	Abnormal	Abnormal	Changes	RPE Normal	Not performed	Screening Amsler Q5: colour tint above/below black spot. Formal Amsler: discoloration behind grid ?significance
	14	6/4, 6/4	Improved (+)	No change	Normal	Normal	Changes	Granularity/pigmentation of RPE Normal	Not performed	
	15	6/6, 6/5	Reduced (-)	1 colour plate worse than baseline	Normal	Normal	Normal	Normal	Not performed	
	16	6/6, 6/5	Reduced (-)	1 colour plate worse than baseline	Normal	Normal	Changes	Normal	Not performed	
	17	6/5, 6/4	No change	No change	Normal	Normal	Normal	Normal	Not performed	
	18	6/5, 6/5	Improved (+)	No change	Normal	Normal	Changes	Granularity/pigmentation of RPE Normal	Not performed	Macula pigment irregularity R>L
	19	6/5, 6/5	Improved (+)	No change	Normal	Normal	Changes	Normal	Not performed	
	21	6/5, 6/5	Improved (+)	No change	Normal	Normal	Normal	Normal	Not performed	
	23	6/5, 6/5	Reduced (-)	No change	Normal	Normal	Changes	Normal	Not performed	

A = Treatment A: TAFENOQUINE 200MG 3 DAYS FOLLOWED BY 200MG WEEKLY  
B = Treatment B: MEFLOQUINE 250MG 3 DAYS FOLLOWED BY 250MG WEEKLY



## Appendix F: List of individual subjects with eye findings at 6 months including change from baseline

Treatment	Coded ID	Visual Acuity at 6 mths	Change in Visual Acuity	Change in Colour Vision	Screening Amsler at 6 mth	Formal Amsler at 6 mth	Corneal Changes	Macula at 6 months	Flourescein angiogram at 6 mths	Comments
A	24	6/6, 6/6	No change	No change		Normal	Changes	Normal	Not performed	Linear vortex corneal verticillata
	25	6/5, 6/5	Improved (+)	1 colour plate worse than baseline plus drusen	Normal	Normal	Changes	Granularity/pigmentation either within normal limits or abnormal,	Not performed	
	26	6/6, 6/6	Reduced (-)	No change	Normal	Normal	Changes	Normal	Not performed	Formal Amsler post dilatation Q3: "Edges of square slightly blurred"
	27	6/5, 6/4	Improved (+)	No change	Normal	Normal	Changes	Granularity/pigmentation of RPE	Performed	
	28	6/4, 6/4	No change	No change	Normal	Normal	Changes	Granularity/pigmentation of RPE but within normal limits	Not performed	
	29	6/5, 6/5	Reduced (-)	No change	Normal	Normal	Changes	Granularity/pigmentation of RPE but within normal limits	Not performed	
	30	6/6, 6/5	Improved (+)	No change	Normal	Normal	Changes	Granularity/pigmentation either within normal limits or abnormal, plus drusen	Not performed	Macular granulation and occasional drusen. Screening Amsler Q3: edge of border blurred, Q5 vibration of all lines.
	31	6/5, 6/4	Improved (+)	No change	Abnormal	Normal	Changes	Normal	Not performed	Formal Amsler post-dilatation Q5: "Having of lines". Colour plates 11 errors compared to 13.
	32	6/6, 6/6	No change	2 colour plates worse than baseline	Normal	Normal	Changes	Normal	Not performed	

A = Treatment A: TAFENOQUINE 200MG 3 DAYS FOLLOWED BY 200MG WEEKLY  
B = Treatment B: MEFLOROQUINE 250MG 3 DAYS FOLLOWED BY 250MG WEEKLY

## Appendix F: List of individual subjects with eye findings at 6 months including change from baseline

Treatment ID	Coded ID	Visual Acuity at 6 mths	Change in Visual Acuity	Change in Colour Vision	Screening Amsler at 6 mth	Formal Amsler at 6 mth	Corneal Changes	Macula at 6 months	Flourescein angiogram at 6 mths	Comments
A	33	6/5, 6/5	Reduced (-)	No change	Normal	Normal	Normal	Granularity/pigmentation of RPE but within normal limits	Not performed	Macula NAD
	34	6/5, 6/5	No change	2 colour plates worse than baseline	Normal	Normal	Changes	Normal	Performed	
	40	6/4, 6/4	No change	No change	Abnormal	Normal	Changes	Normal	Not performed	Screening Amsler Q5: vibration on lines.
	41	6/5, 6/5	Improved (+)	No change	Normal	Normal	Changes	Normal	Not performed	Macular granulation R>L.
	42	6/5, 6/5	Improved (+)	No change	Normal	Normal	Changes	Granularity/pigmentation of RPE	Not performed	Congenital lens opacity
	44	6/5, 6/5	No change	No change	Normal	Normal	Changes	Normal	Not performed	
	45	6/4, 6/4	No change	No change	Normal	Normal	Changes	Granularity/pigmentation of RPE	Not performed	
	46	6/6, 6/6	No change	1 colour plate better than baseline	Normal	Normal	Changes	Normal	Performed	Formal Amsler post-dilatation Q3: 'saw x'
	47	6/6, 6/6	No change	No change	Normal	Normal	Changes	Normal	Not performed	Minimal epithelial whirls
	48	6/6, 6/6	No change	No change	Normal	Normal	Changes	Normal	Not performed	
	49	6/6, 6/6	No change	1 colour plate worse than baseline	Normal	Normal	Changes	Normal	Not performed	
	50	6/4, 6/4	Improved (+)	No change	Normal	Normal	Changes	Granularity/pigmentation of RPE	Not performed	
	51	6/5, 6/5	Improved (+)	No change	Normal	Normal	Possible changes	Normal	Not performed	

03 JUL 2001

A - Treatment A: TAFENOQUINE 200MG 3 DAYS FOLLOWED BY 200MG WEEKLY  
B - Treatment B: MEFLOROQUINE 250MG 3 DAYS FOLLOWED BY 250MG WEEKLY

## Appendix F: List of individual subjects with eye findings at 6 months including change from baseline

Treatment ID	Coded ID	Visual Acuity at 6 mths	Change in Visual Acuity	Change in Colour Vision	Screening Amsler at 6 mth	Formal Amsler at 6 mth	Corneal Changes	Macula at 6 months	Flourescein angiogram at 6 mths	Comments
A	52	6/5, 6/5	No change	No change	Normal	Normal	Changes	Granularity/pigmentation of RPE but within normal limits	Not performed	Early lens changes - normal for past exposure to UV
	53	6/5, 6/5	No change	No change	Normal	Normal	Changes	Granularity/pigmentation either within normal limits or abnormal, plus drusen	Not performed	
	55	6/4, 6/4	No change	No change	Normal	Normal	Changes	Granularity/pigmentation of RPE	Performed	Early cortical lens changes (within normal limits)
	56	6/6, 6/6	Improved (+)	1 colour plate worse than baseline	Normal	Normal	Changes	Normal	Not performed	
	57	6/5, 6/5	Reduced (-)	No change	Normal	Normal	Possible changes	Normal	Not performed	
	58	6/6, 6/6	Reduced (-)	No change	Normal	Normal	Changes	Normal	Not performed	
	59	6/4, 6/4	Improved (+)	No change	Normal	Normal	Changes	Normal	Not performed	
	60	6/6, 6/6	No change	No change	Normal	Normal	Changes	Granularity/pigmentation of RPE but within normal limits	Not performed	
	61	6/5, 6/5	Reduced (-)	No change	Normal	Normal	Changes	Granularity/pigmentation of RPE but within normal limits	Not performed	
	64	6/4, 6/4	No change	No change	Normal	Normal	Changes	Granularity/pigmentation of RPE but within normal limits	Not performed	
	65	6/4, 6/4	No change	No change	Normal	Normal	Changes	Granularity/pigmentation of RPE but within normal limits	Not performed	
	66	6/4, 6/4	Improved (+)	No change	Abnormal	Normal	Possible changes	Granularity/pigmentation of RPE but within normal limits	Not performed	Screening Amsler Q2: couldn't see points of corners, Q3 blurred area on left side. Old

corneal scar.

A - Treatment A: TAFENOQUINE 200MG 3 DAYS FOLLOWED BY 200MG WEEKLY  
B - Treatment B: MEFLOQUINE 250MG 3 DAYS FOLLOWED BY 250MG WEEKLY

03 JUL 2001

## Appendix F: List of individual subjects with eye findings at 6 months including change from baseline

Treatment ID	Coded ID	Visual Acuity at 6 mths	Change in Visual Acuity	Change in Colour Vision	Screening Amsler at 6 mth	Formal Amsler at 6 mth	Corneal Changes	Macula at 6 months	Flourescein angiogram at 6 mths	Comments
A	67	6/4, 6/4	Improved (+)	No change	Normal	Normal	Changes	Granularity/pig mentation of RPE	Not performed	Macula - mild granular changes R & I macula region R>L.
	69	6/4, 6/6	Improved (+)	No change	Normal	Normal	Possible changes	Normal	Not performed	
	70	6/4, 6/5	Improved (+)	No change	Normal	Normal	Changes	Granularity/pig mentation of RPE	Not performed	
	71	6/5, 6/5	Reduced (-)	No change	Normal	Normal	Changes	Normal	Not performed	
	72	6/5, 6/5	Improved (+)	No change	Normal	Normal	Changes	Normal	Not performed	
	73	6/9, 6/12	Reduced (-)	2 colour plates worse than baseline	Normal	Normal	Changes	Granularity/pig mentation of RPE	Performed*	Previous Lasik scars
	74	6/9, 6/6	Reduced (-)	1 colour plate worse than baseline	Normal	Normal	Changes	Granularity/pig mentation either within normal limits or abnormal, plus drusen	Not performed	With glasses and has had previous bilateral Lasik surgery. Drusen on R.
	75	6/5, 6/5	Improved (+)	No change	Normal	Normal	Changes	Granularity/pig mentation of RPE	Performed	
	76	6/4, 6/4	Improved (+)	No change	Normal	Normal	Changes	Granularity/pig mentation of RPE but within normal limits	Not performed	
	78	6/6, 6/6	No change	No change	Normal	Normal	Changes	Normal	Not performed	Screening Amsler
	79	6/5, 6/5	Reduced (-)	1 colour plate worse than baseline	Abnormal	Normal	Changes	Normal	Not performed	Q3: saw white/black spots over sheet, Q5: saw black colour
	80	6/4, 6/4	No change	No change	Normal	Normal	Changes	Granularity/pig mentation of RPE	Not performed	

\*performed at follow-up visit

A = Treatment A: TAPEOQUINE 200MG 3 DAYS FOLLOWED BY 200MG WEEKLY  
B = Treatment B: MEFLOROQUINE 250MG 3 DAYS FOLLOWED BY 250MG WEEKLY

03 JUL 2001



Appendix F: List of individual subjects with eye findings at 6 months including change from baseline

Treatment	ID	Visual Acuity at 6 mths	Change in Visual Acuity	Change in Colour Vision	Screening Amsler at 6 mth	Formal Amsler at 6 mth	Corneal Changes	Macula at 6 months	Flourescein angiogram at 6 mths	Comments
A	83	6/4, 6/4	No change	No change	Normal	Normal	Normal	Normal	Not performed	Drusen R eye
	85	6/5, 6/5	Improved (+)	No change	Normal	Normal	Changes	Drusen	Not performed	Screening Amsler
	87	6/5, 6/5	No change	1 colour plate worse than baseline	Abnormal	Normal	Changes	Normal	Not performed	Q3: "not really blurred", Q5: "slight vibration in lines" Corneal old scar on R
	89	6/5, 6/5	Reduced (-)	No change	Normal	Normal	Changes	Normal	Not performed	
	92	6/6, 6/6	No change	1 colour plate worse than baseline	Normal	Normal	Changes	Normal	Not performed	
	93	6/4, 6/4	No change	1 colour plate worse than baseline	Normal	Normal	Changes			
B	94	6/6, 6/6	No change	No change	Normal	Normal	Changes	Granularity/pigmentation of RPE but within normal limits	Not performed	Formal Amsler post-dilatation
	95	6/6, 6/6	No change	No change	Normal	Normal	Changes	Granularity/pigmentation of RPE	Not performed	Q3: "Saw black spot mid left bottom"
	7	6/5, 6/4	Improved (+)	No change	Normal	Normal	Normal	Normal	Not performed	
	20	6/5, 6/5	Reduced (-)	No change	Normal	Normal	Normal	Normal	Not performed	
	22	6/6, 6/6	No change	No change	Normal	Normal	Normal	Normal	Not performed	
	35	6/5, 6/5	Improved (+)	No change	Normal	Normal	Normal	Granularity/pigmentation of RPE but within normal limits	Not performed	
	36	6/5, 6/5	Improved (+)	No change	Normal	Normal	Normal	Normal	Not performed	
	37	6/6, 6/6	Reduced (-)	1 colour plate worse than baseline	Normal	Normal	Normal	Normal	Not performed	

A = Treatment A: TAFENOQUINE 200MG 3 DAYS FOLLOWED BY 200MG WEEKLY  
B = Treatment B: MEFLOQUINE 250MG 3 DAYS FOLLOWED BY 250MG WEEKLY

## Appendix F: List of individual subjects with eye findings at 6 months including change from baseline

Treatment ID	Coded ID	Visual Acuity at 6 mths	Change in Visual Acuity	Change in Colour Vision	Screening Amsler at 6 mth	Formal Amsler at 6 mth	Corneal Changes	Macula at 6 months	Flourescein angiogram at 6 mths	Comments
B	38	6/4, 6/4	No change	No change	Normal	Normal	Normal	Granularity/pigmentation of RPE	Performed	
	39	6/5, 6/5		No change	Normal	Normal	Normal	Granularity/pigmentation of RPE	Not performed	VA not recorded pre-deployment.
	43	6/5, 6/5	Improved (+)	1 colour plate better than baseline	Normal	Normal	Normal	Granularity/pigmentation of RPE	Not performed	
	54	6/6, 6/6	No change	No change	Normal	Normal	Normal	Granularity/pigmentation of RPE	Not performed	
	62	6/5, 6/5	Improved (+)	No change	Normal	Normal	Normal	Granularity/pigmentation of RPE	Not performed	
	63	6/6, 6/6	Reduced (-)	2 colour plates worse than baseline	Normal	Normal	Normal	Granularity/pigmentation of RPE	Not performed	
	68	6/5, 6/5	Improved (+)	No change	Abnormal	Normal	Normal	Granularity/pigmentation of RPE	Not performed	Screening Amsler Q5: saw diagonal lines through the page, going from dark to light
	77	6/5, 6/5	No change	No change	Abnormal	Normal	Normal	Granularity/pigmentation of RPE	Not performed	Screening Amsler Q3: Blurred outside the square, slight waving of lines
	81	6/4, 6/4	Improved (+)	1 colour plate worse than baseline	Normal	Normal	Normal	Granularity/pigmentation of RPE	Not performed	
	82	6/4, 6/4	No change		Normal	Normal	Normal	Granularity/pigmentation of RPE	Not performed	
	84	6/4, 6/4	Improved (+)	No change	Normal	Normal	Normal	Granularity/pigmentation of RPE	Not performed	

A = Treatment A: TAPENOQUINE 200MG 3 DAYS FOLLOWED BY 200MG WEEKLY  
B = Treatment B: NEFLOQUINE 250MG 3 DAYS FOLLOWED BY 250MG WEEKLY

Appendix F: List of individual subjects with eye findings at 6 months including change from baseline

Treatment ID	Coded ID	Visual Acuity at 6 mths	Change in Visual Acuity	Change in Colour Vision	Screening Amsler at 6 mth	Formal Amsler at 6 mth	Corneal Changes	Macula at 6 months	Flourescein angiogram at 6 mths	Comments
B	86	6/6, 6/6	No change	2 colour plates worse than baseline	Normal	Normal	Normal	Normal	Not performed	
	88	6/6, 6/9	Reduced (-)	No change	Normal	Normal	Normal	Normal	Not performed	
	90	6/4, 6/9	Improved (+)	No change	Normal	Normal	Normal	Normal Drusen	Not performed	Macula occasional drusen
	91	6/6, 6/6	Reduced (-)	1 colour plate worse than baseline	Normal	Normal	Normal	Normal	Not performed	

A = Treatment A: TAFENOQUINE 200MG 3 DAYS FOLLOWED BY 200MG WEEKLY  
 B = Treatment B: MEFLOROQUINE 250MG 3 DAYS FOLLOWED BY 250MG WEEKLY



*Memorandum*

**To:** Investigators involved in any previously completed  
TAFENOQUINE clinical study (Phase I and Phase II programme)

**From:** GlaxoSmithKline

**Date:** 3-July-2001

**Subject:** IND Safety Report – Tafenoquine (SB 252263, WR  
238605) IND 38,503

---

In accordance with Regulatory guidelines and GlaxoSmithKline (GSK) policy, we are providing you with copies of **three IND Safety Reports**.

The **first** safety report ( dated 3rd Jul 2001) relates to preliminary results of preclinical findings of renal tumours in a 2-year rat carcinogenicity study. A summary of this finding is given below and full details are covered in the IND Safety Report enclosed.

The first new safety alert relates to a finding in the rat carcinogenicity study. Tafenoquine treatment (2.0 mg/kg/day orally for 2 years) appears to be associated with an increased incidence of renal cell tumours and hyperplasia in male rats. Kidneys of males from other dose groups (1.0, 0.5 and 0.1 mg/kg/day) are being evaluated. Drug-induced increases in kidney tumors were not observed in female rats given 2.0 mg/kg/day. The equivalent mouse study is not expected to report till mid-2003 so comparative data in that species are not available. The mechanism appears to be non-genotoxic and related to daily dosing for periods approaching the lifetime of the rats, in the context of clinical trial use the weight of current evidence indicates that the findings in the rat carcinogenicity study do not predict any hazard to human in the studies conducted to date.

Additionally in this package, we are providing you with copies of **two further IND Safety Reports**. The findings relate to ocular changes observed in the following clinical study:

Study 252263/033 ADMEC No. 216/00

03 JUL 2001

A randomised, double-blind, comparative study to evaluate the safety, tolerability and effectiveness of tafenoquine and mefloquine for the prophylaxis of malaria in non-immune Australian soldiers deployed to East Timor.

Summaries of the findings in the two clinical IND Safety Reports are provided below with details being covered in the two full IND Safety Reports enclosed. The initial report is dated 09-May 2001 and the follow-up report 03-July 2001.

Please note that the 9th May 2001 report was only provided to investigators involved in ongoing studies at the time. Since then, GSK has been asked for information on these findings from other investigators involved in completed studies and therefore GSK is now providing the two new safety updates and the previous one to all investigators involved in completed studies.

In accordance with Good Clinical Practice, please promptly inform your Ethics Committee/Investigational Review Board, Regulatory Authorities (where involved), co-investigators and study co-ordinators of the content of all three safety reports. Please file this letter with your Investigator Brochure/Study File.

03 JUL 2001



### **Summary of Clinical Findings in Initial Safety Report of 09-May 2001**

The data were from a subset of subjects ( $n = 33/99$ ) in a Phase III study (Study 252263/033) investigating the safety, tolerability and effectiveness of tafenoquine in the prophylaxis of malaria in non-immune Australian soldiers deployed to East Timor. These subjects had received 6 months study medication with TAFENOQUINE or mefloquine and are part of a subset that are being monitored for possible effects of phospholipidosis due to observations in animal toxicology studies (see next section).

In the initial Safety Report, ophthalmological (corneal examination, visual acuity, visual field) and lung function testing (diffusing capacity of carbon monoxide –  $D_LCO$ ) data were presented on the first 33 soldiers within this subset, 26 of whom were receiving tafenoquine and 7 of whom were receiving mefloquine. After 6 months weekly dosing corneal changes (a vortex keratopathy) had been seen in 25 of 26 tafenoquine subjects, but in none of the 7 mefloquine subjects. Amsler grid examinations suggested mild visual field changes in 4 tafenoquine subjects, but not mefloquine subjects. Minor visual acuity changes were reported across both treatment groups. All examinations were normal at baseline.

This affected three studies: the uncompleted Study 252263/033, a compassionate use study in treatment of recurrent *P. vivax* recurrence (Study 252263/046) and a paediatric study in prevention of *P. vivax* relapse (Study 252263/036). Dosing in these studies was voluntarily suspended by GlaxoSmithKline Beecham on the 1st May 2001 as a result of these findings.

### **Summary of Clinical Findings in Second Safety Report of 03-July 2001**

The purpose of the **second Safety Report** is to update Regulatory Agencies, Ethics Committees and Investigators of safety findings related to the total subset of subjects involved in the monitoring for the effects of phospholipidosis in Study 252263/033. Since the initial report, ophthalmological and lung function testing has been performed on the complete subset in this study, a total of 95 subjects, with baseline and end of study assessments (four subjects from the total included in the initial report [ $n=99$ ] did not complete the study and therefore do not have end of study assessments).

Details of the examinations are given in the Safety Report, but in summary, across the 95 subjects the following findings are reported:

03 JUL 2001

- 1) corneal changes (a vortex keratopathy) have been seen in 65 of 74 tafenoquine subjects, but in none of the 21 mefloquine subjects
- 2) minor visual acuity and colour vision changes were reported across both treatment groups
- 3) on a screening Amsler grid assessment possible mild visual field changes were reported in 8 tafenoquine subjects, and in 2 mefloquine subjects. However, on formal Amsler grid assessment only one was abnormal (a tafenoquine subject)
- 4) retinal examinations demonstrate granularity/pigmentation of the retinal pigment epithelium (RPE) in 22 tafenoquine subjects and 2 mefloquine subjects; hard drusen were seen in 6 tafenoquine subjects and 1 mefloquine subject

All examinations were reported as normal at baseline (before study medication).

- 5) A group of 10 subjects with retinal changes (9 tafenoquine subjects and 1 mefloquine subject), proceeded to fluorescein angiogram examination. Seven examinations were reported as normal, three had abnormalities (2 tafenoquine subjects and 1 mefloquine subject).

### **Clinical Findings and Proposed Next Steps**

These clinical observations are very recent, and the picture is constantly evolving as results from additional and follow-up investigations are gathered. Although a clear corneal effect has been observed, evidence from other cationic amphiphilic agents suggest that this will be reversible. For this reason the subjects from this study are being followed for resolution of the corneal deposits; the next assessment of subjects will be made in August 2001, this being equivalent to approximately 12 weeks off study drug.

The significance of the retinal observations is being discussed with external ophthalmological experts. The discussions include further characterisation and the clinical relevance of these findings, and additional investigations in the current Study 033, or in possible additional studies, to either confirm or exclude a retinal effect.

The development partners of TAFENOQUINE, GlaxoSmithKline and the US Army, believe that results from those additional investigations and expert discussions are needed to indicate whether at the present time or in the future wider investigations or examinations of subjects involved in earlier Phase I and II studies are warranted.

When we have completed our follow up examinations and consultation with experts we intend to communicate this information with you at the earliest opportunity.

03 JUL 2001